

Case Report

Oral necrotizing fasciitis of the buccal mucosa

Yi-Tzu Chen^{12*}, Chih-Yu Peng¹², Ming-Yi Lu¹², Yu-Wei Chiu¹²

¹ School of Dentistry, Chung Shan Medical University

² Department of Oral and Maxillofacial Surgery, Chung Shan Medical University Hospital

Necrotizing fasciitis can present in the head and neck region with rapid progression after odontogenic infection, but is uncommon. Non-odontogenic necrotizing fasciitis is even more rare and can be difficult to diagnosis initially. Early recognition and surgical intervention are crucial. A 48-year-old male accidentally bit his cheek 5 days prior to coming to our hospital. There was swelling over the right side of his face that involved the submandibular space and submental space for 3 days with high fever. The lower right buccal vestibule showed diffuse swelling with erosion. The underlying systemic diseases were diabetes mellitus and hypertension. On computed tomography scan, there was soft tissue swelling over right mandibular region. After 3 days of antibiotic therapy, the swollen area showed generalized necrotic mucosa formation. Treatment was started immediately including incision, drainage, and full debridement. The tissue biopsy showed generalized necrotic mucosa. The pus culture showed the presence of monomicrobial *Klebsiella pneumoniae*. Antibiotic therapy was continued in addition to daily irrigation and change of dressing until full recovery. Generally, surgical intervention cannot be as aggressive on the face as in the extremities or trunk, since many vital structures are concentrated in a relatively small area. Broad-spectrum intravenous antibiotics and surgical debridement remain the mainstays of treatment.

Keywords: biting trauma, monomicrobial *Klebsiella pneumoniae*, oral necrotizing fasciitis

Introduction

Necrotizing fasciitis(NF) is a rapidly progressive soft tissue infection. Its occurrence in the head and neck region is uncommon and usually arises from infections of odontogenic or pharyngeal origin(1). It affects men more frequently than women, in a 2:1 proportion(2). NF of the face is rare. Shindo et al. reported 4 cases and reviewed 35 cases of NF of the face in 1997(3). Delay in diagnosis may lead to rapid progression. Patients often present with systemic diseases or immunosuppression that predispose them

to this condition.

Poorly controlled diabetes, hypertension, alcoholism, atherosclerosis, malnutrition and smoking are significant predisposing factors(4). We present a case of NF of the oral cavity resulting from biting trauma.

Case Report

A 48-year-old male presented with right face and lower right lip swelling involving the buccal, submandibular, and submental spaces for 3 days with intermittent fever of up to 39°C. He stated that he had accidentally bitten his cheek 2 days prior to the swelling, and he had been treated at a local dental clinic in China. However, there was no improvement and the swelling extended to the right face and neck. Swelling was also associated with

* Corresponding Author: Yi-Tzu Chen

Mailing address: Department of Oral and Maxillofacial Surgery, Chung Shan Medical University Hospital
Address: No.110, Sec.1, Jianguo N. Rd., Taichung City 40201, Taiwan.
Tel: +886-4-24718668 ext. 55153

sore throat and numbness over the lower right lip. Due to the progression of the swelling, he visited our emergency department. On examination, indurated and boardlike swelling of approximately 6 × 3 cm with erosive mucosal surface over the lower lip and right buccal vestibule area, accompanied by limited mouth opening, were noted.

The patient had poorly controlled diabetes mellitus. He also presented with hypertension that was managed with medication. Initial data showed white blood cell count, glucose count, C-reactive protein, and HbA_{1c} of 22710/mm³, 282 mg/dL, 21.869, and 11.1, respectively. Computed tomography scan revealed diffuse soft tissue swelling of the subcutaneous layer over the right submandibular region and thickening of the right platysma with little accumulation of pus (Fig. 1). Although we diagnosed his condition as cellulitis over the right cheek, lower lip, right submental space, and submandibular space, the origin could not be defined. After 3 days of empiric antibiotic therapy, the swelling progressed and presented with generalized necrotic mucosa over the lower anterior vestibule. We checked for possible initiating factors and determined a plan for surgery.

Dental conditions were fair on oral exam and panoramic radiograph. We started incision and drainage, followed by full debridement of the necrotic tissue under general anesthesia on two separate occasions (Fig. 2). The pus culture showed presence of monomicrobial *Klebsiella pneumoniae* and the tissue biopsy showed generalized necrotic tissue of the cheek (Fig.3). The minor salivary gland

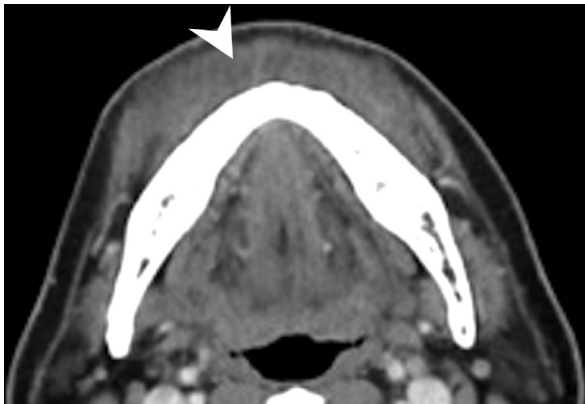


Fig.1 Computed tomography scan showing diffuse soft tissue swelling of the subcutaneous layer (arrow head) over the entire lower lip and cheek.

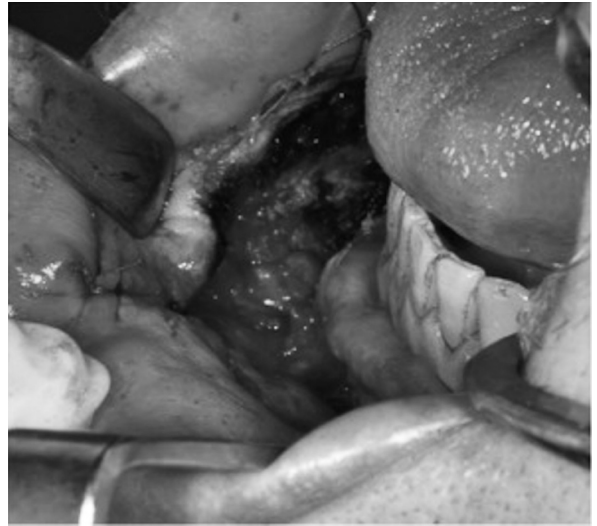

Fig.2 Full debridement of the necrotic tissue over the lower anterior vestibule under general anesthesia (the second surgery).

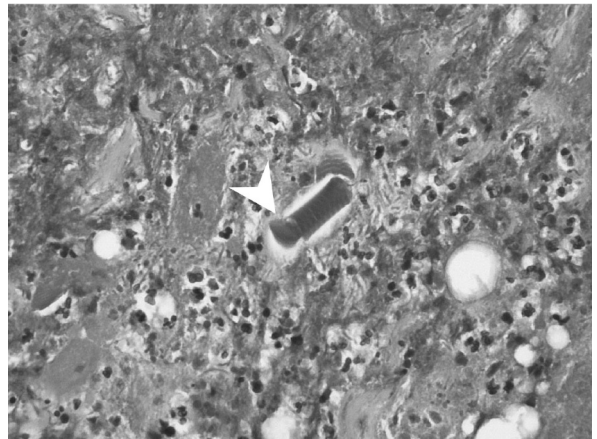


Fig.3 Histopathologic study showed neutrophil infiltration with pus accumulation in muscle layer and unknown foreign body in the tissue (arrow head).

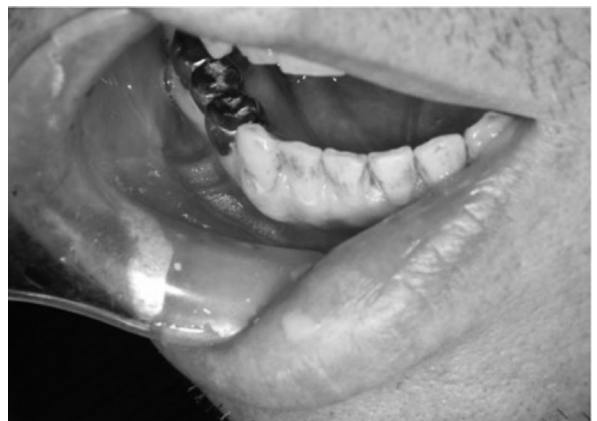

Fig.4 Complete wound healing 10 weeks after surgery.

was still intact and not the source of infection. With daily irrigation and change of dressing, the wound healed by secondary intention until full recovery with minimal scar formation (Fig. 4).

Discussion

Odontogenic infection is the frequent mechanism of facial NF and diabetes mellitus is the most commonly associated systemic disease. Nonodontogenic NF is rare, with possible origins including infections of the tonsils or the pharynx, blunt trauma, irradiation, cervical adenitis, gunshot wound, and salivary glands(5). Subcutaneous gas and abscess formation can be seen on computed tomographic image, although this modality is not very sensitive. The most commonly isolated microorganism is group A *Streptococcus*(6), but polymicrobial infection is possible. However, the prevalence of monomicrobial NF has been reported to be as high as 60%–80%(7).

Studies have reported that *K. pneumoniae* is one of the common pathogens responsible for NF, as observed in our case, especially in monomicrobial infection under poorly controlled diabetic conditions(8, 9). Monomicrobial NF caused by *K. pneumoniae* is extremely rare in the Western hemisphere(10), but is more common among the Asian population, which poses the question of host genetic susceptibility versus geographically defined pathogen exposure and acquisition(11).

Aggressive surgical intervention cannot be performed in the facial region due to esthetic reasons and the concentration of vital structures in a relatively small area(12). Thus, when considering esthetic repair, broad-spectrum intravenous antibiotics and surgical debridement, such as performed in this study, are still the mainstays of treatment.

References

1. Wolf H, Rusan M, Lambertsen K, Ovesen T. Necrotizing fasciitis of the head and neck. *Head & neck*. 2010;32(12):1592-6.
2. Quereshy FA, Baskin J, Barbu AM, Zechel MA. Report of a case of cervicothoracic necrotizing fasciitis along with a current review of reported cases. *Journal of Oral and Maxillofacial Surgery*. 2009;67(2):419-23.
3. Shindo ML, Nalbone VP, Dougherty WR. Necrotizing fasciitis of the face. *The Laryngoscope*. 1997;107(8):1071-9.
4. Majeski JA, Alexander JW. Early diagnosis, nutritional support, and immediate extensive debridement improve survival in necrotizing fasciitis. *American journal of surgery*. 1983;145(6):784-7.
5. Tovi F, Fliss DM, Zirkin HJ. Necrotizing soft-tissue infections in the head and neck: a clinicopathological study. *The Laryngoscope*. 1991;101(6 Pt 1):619-25.
6. Alvarez Hernández DA CvA, Rivera AS. Facial necrotizing fasciitis in adults: a systematic review. *Heighpubs Otolaryngol and Rhinol*. 2017(1):020-31.
7. Tsai YH, Huang KC, Shen SH, Hsu WH, Peng KT, Huang TJ. Microbiology and surgical indicators of necrotizing fasciitis in a tertiary hospital of southwest Taiwan. *International journal of infectious diseases: IJID: official publication of the International Society for Infectious Diseases*. 2012;16(3):e159-65.
8. Cheng NC, Yu YC, Tai HC, Hsueh PR, Chang SC, Lai SY, et al. Recent trend of necrotizing fasciitis in Taiwan: focus on monomicrobial *Klebsiella pneumoniae* necrotizing fasciitis. *Clinical infectious diseases: an official publication of the Infectious Diseases Society of America*. 2012;55(7):930-9.
9. Hidaka H, Yamaguchi T, Hasegawa J, Yano H, Kakuta R, Ozawa D, et al. Clinical and bacteriological influence of diabetes mellitus on deep neck infection: Systematic review and meta-analysis. *Head & neck*. 2015;37(10):1536-46.
10. Kohler JE, Hutchens MP, Sadow PM, Modi BP, Tavakkolizadeh A, Gates JD. *Klebsiella pneumoniae* necrotizing fasciitis and septic arthritis: an appearance in the Western hemisphere. *Surgical infections*. 2007;8(2):227-32.
11. Shon AS, Bajwa RP, Russo TA. Hypervirulent (hypermucoviscous) *Klebsiella pneumoniae*: a new and dangerous breed. *Virulence*. 2013;4(2):107-18.
12. Lee JT, Hsiao HT, Tzeng SG. Facial necrotizing fasciitis secondary to accidental bite of the upper lip. *The Journal of emergency medicine*. 2011;41(1):e5-8.